

Epicapsular Stars

The picture shows a cluster of small brown star-shaped deposits on the anterior lens capsule which are known as 'Epicapsular Stars'. They may be single or multiple and occur unilateral or bilateral. Epicapsular Stars are remnants of the tunica vasculosa lentis, which nourishes the crystalline lens during the early development of the eye.

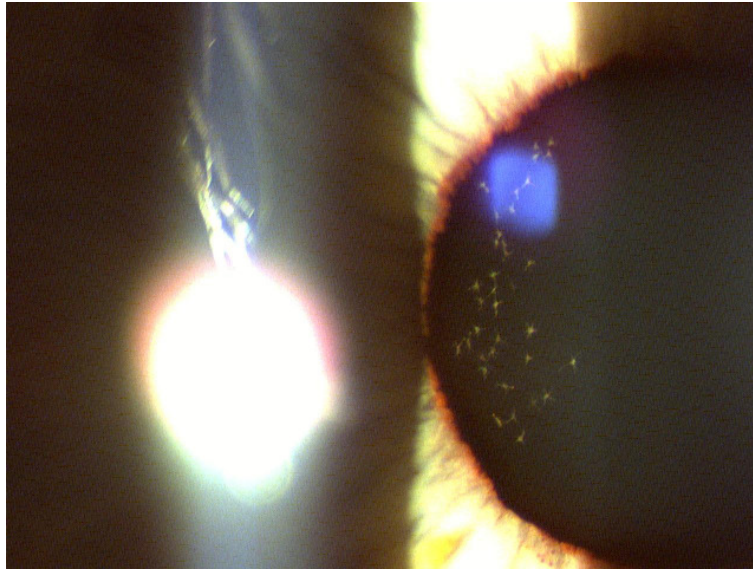


Abbildung 1: Epicapsular Stars